



Abdisa Tagesu*

Jimma University, School of Veterinary Medicine, Jimma, Oromia, Ethiopia

Received: 14 May, 2018

Accepted: 13 August, 2018

Published: 14 August, 2018

*Corresponding author: Abdisa Tagesu, Jimma University, School of Veterinary Medicine, Jimma, Oromia, Ethiopia, Tel: +251933681407, E-mail: abdisatagesu@gmail.com

<https://www.peertechz.com>

Research Article

Physical Examination

Physical examination is the methods of examination by means of applying general inspection, palpation, percussion and auscultation of animals to detect clinical signs of patient animals. General inspection is done some distance away from the animal; sometimes go round the animal or herd/flock, in order to get the general impression about the case¹. Attention should be compensated to the following items: behavior, appetite, defecation, urination, pasture, gait, body condition, body conformation, and lesions on outer surface of the body.

Palpation

Palpation is used to detect the presence of pain in a tissue by noting increased sensitivity and use fingers, palm, back of the hand, and fist, in order to get the information about the variation in size, shape, consistency and temperature of body parts and lesions, e.g., the superficial lymph nodes. The terms, which can be used to describe the consistency of parts during palpation, are [2,3].

- * **Resilient:** When a structure quickly resumes its normal shape after the application of pressure has ceased (e.g., Normal rumen)
- * **Doughy:** When pressure causes pit ting as in edema
- * **Firm:** When the resistance to pressure is similar to that of the normal liver (neoplasia/tumor)
- * **Hard:** When the structure possesses bone-like consistency (Actinomycotic lesion)
- * **Fluctuating:** When a wave-like movement is produced in a structure by the application of alternate pressure (hernia, hemorrhage/hematoma)
- * **Emphysematous:** When the structure is swollen and yields on pressure with the production of a crepitating or crackling sound (Table 1).

Percussion

Percussion is the methods of examination in which part of body to be examined is struck with sharp blow using fingertips to produce audible sound. Sound thus emitted will indicate the nature of the tissue / organ involved for example rumen when bloated will emit drum like sound. Some of the organs that can be examined by percussion are: gastro-intestinal tract, abdomen and thorax, frontal and nasal sinuses. The objectives of percussion are to obtain information about the condition of the surrounding tissues and, more particularly, the deeper lying parts. Percussion can examine the area of the subcutaneous emphysema, lungs, rumen and rump. Sounds produced from various structures can be described as following list [2,4,5].

- * Dull / flat: sound without resonance or echo, this type of sound can be heard on percussion of thick muscles or bone.
- * Full sound: sound heard is with resonance but not booming like drum. This type of sound is heard from tissues like lungs that contain air inside.
- * Tympanic sound: drum like sound can be heard, and this type of sound is heard from bloated rumen, abomasums and intestine.

Types of percussion

Immediate percussion: Using fingers or hammer directly strike the parts being examined.

Mediate percussion: Finger-finger percussion; Pleximeter-

Table 1: The structures that can be palpated and what they are palpated for.

Organs	Palpated For
Superficial Arteries	Pulse
Uterus	Pregnancy
Muscles	Pain/Swelling
Bone	Fracture/Growth
Stomach, Intestine	Pain
Esophagus	Obstruction
Rumen	Bloat, Impaction

hammer percussion. The quality of the sounds produced by percussion is classified as ⁴:

- **Resonant:** This is characteristic of the sound emitted by air containing organs, such as the lungs.
- **Tympanic:** The sound produced by striking a hollow organ containing gas under pressure, (tympanitic rumen or caecum).
- **Dull:** Sound emitted by a solid organ like the liver or heart.

Ballottement percussion: Tactile percussion or ballottement: is method in which palpation and percussion are combined together to feel structures that cannot be felt by either of these methods applied singly. This is normally used for pregnancy diagnosis in cows when the foetus cannot be palpated through per rectum. Here a firm–pushing stroke is applied on to the uterus and the hand after pushing is kept in contact with uterus so that the foetus will bound and strike on it. While firm pushing is done, this sets fluid in uterus into motion and foetus is made to bounce ². This modified percussion is used to detect late pregnancy in small ruminants, dogs and cats. And also, used for detection rebound of floated material shows pregnancy. Procedure: Apply a firm and interrupted push on the uterine region of the abdomen of small ruminants.

Fluid percussion: Used to detect fluid in the abdomen

Procedure: Apply a push on one side of the abdomen, percussion on the other side. The presence of wave–like fluid movement shows accumulation of fluid in the abdomen, ascites [6,7].

Auscultation

Word auscultation comes from ‘auscultona’ meaning ‘to listen’. This is a technique of listening to the sounds produced from organs in the abdominal and thoracic cavities. In olden days listening to these sounds were done with naked ears. This had certain limitations like the skin on animal being dirty and infested by parasites it was not healthy for the clinicians and was difficult to keep ears in contact on animal body due to constant movement. Therefore, an instrument was later developed for this purpose and this is called stethoscope [4,6] (Figure 1). The main objective of auscultation is that to listen the sounds produced by the functional activity of an organ located within a part of the body. This method used to examine the lung, trachea, heart and certain parts of the alimentary tract.

Types of auscultation

Direct auscultation: Spread a piece of cloth on the part to be examined using two hands to fix the cloth and keep your ears close to the body, then listen directly.

Indirect auscultation: Fix the probe of the stethoscope firmly on the part of the body to be examined and listen to the sounds produced by the functional activities of the body carefully.

Steps in auscultation: Place the ear piece into the ears, hold the chest piece and give a gentle tap on diaphragm, if no sound is heard adjust it by holding rubber tube with one hand and turning the chest piece with the other until there is ‘click’ sound. Tap again there should be amplified sound heard. Place the chest piece over the desired area and listen to the sound hear or lungs accordingly. Areas for listening to heart and lungs sounds are shown below, for rumen left flank region can be used [6] (Figure 1).

Succussion (shaking)

Succussion is the methods which used to determine the presence of fluid in the body cavities (thoracic and abdominal cavity). It is applied by shaking animals from side to side to set fluid into motions, and then the audible fluid sound is produced. Succussion method is only common in examination of small animals, but it is difficult in large animals [6].

Clinical Examination of the Patient

Physical examination can be carried out by taking vital sign such as; Temperature taking, Pulse taking, Respiration taking, Capillary Refill Time (CRT), Physical body condition, Normal demeanor, Abnormal demeanor [6,8].

Temperature taking

Temperature is the measures of how hot or cold the animal body is. Temperature can be measured by thermometer such as: digital and manual or mercury thermometer (Figure 2). On the basis of the ability to regulate body temperature animals are divided into two groups via homeotherms and poikilotherms. Homeotherms are those animals including man that can regulate their temperature in relation to the environmental temperature. Poikilotherms are those animals that are unable to regulate their body temperature in relation to the environmental temperature (Amphibians, Reptiles and fishes). Heat is generated in the body via the intracellular oxidation of food and the muscular activities. It is lost via the physical process of conduction, convection, and radiation and through the evaporation, respiration and excretion [2].

The body temperature is taken using a mercury or digital electronic thermometer placed carefully into the rectum. The

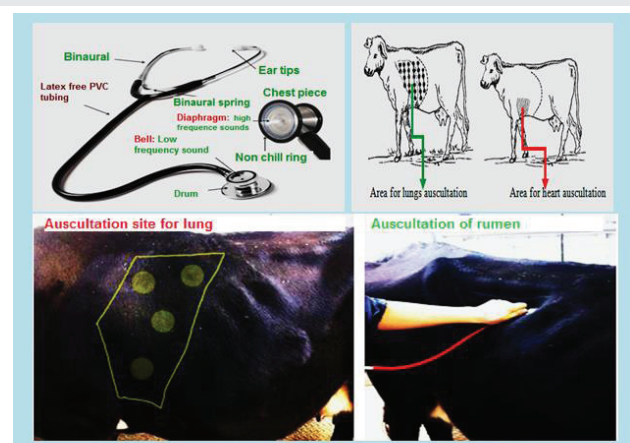


Figure 1: Part of stethoscope and site auscultation for lungs and heart.

thermometer should be lubricated before insertion and checked (in the case of a mercury thermometer) to ensure that the mercury column has been shaken down before use. It should be held whilst it is in the rectum. Sudden antiperistalsis movements in the rectum may pull the thermometer out of reach towards the colon. The thermometer is left in position for at least 30 seconds; the clinician should ensure the instrument is in contact with the rectal mucosa, especially if a lower than expected reading is obtained. The thermometer must be cleaned after removal from the patient. It must not be wiped clean on the patient's coat. If the animal's temperature is higher or lower than anticipated it should be checked again [2,6] (Figure 2).

Procedure: How to take temperature and how to recording temperature [9,10]:

- * The common sites for temperature taking are from rectum and vagina (approximately 0.5 degree centigrade higher in vagina).
- * The thermometer should be sterilized by disinfectant (antiseptics) before use.
- * It should be well shaken before recording of temperature to bring the mercury column below the lowest point likely to be observed in different species of animals. If the reading is not below 36°C, shake the mercury down to the bulb. Use flicking motions, taking care not to hit the thermometer on anything.
- * The bulb end of the thermometer should be lubricated with liquid paraffin or glycerin or soap especially in case of small pup and kitten.
- * Insert the thermometer in a rotational way and gentle manner. Care should be taken so that the bulb of the thermometer remains in contact with the rectal mucous membrane.
- * The thermometer should be kept in site for at least 3-5 minutes.

- * Pull out the thermometer, clean it and read the number.
- * Put a halter or head collar on the horse or donkey and have an assistant hold the head.
- * Read the value to define and explain a state of fever, hypothermia, and febrile or non-febrile animals.
- * The procedure for digital thermometer is different from that of the manual one, in digital thermometer just insertion of thermometer in to rectum of animals and after the time is reached the digital thermometer may give some sound. After that, the clinician should remove and interpret it for examination.

Method of recording temperature:

- * Keep the bulb of the thermometer immersed in the antiseptic solution for sterilization.
- * Bring down the column of the mercury before recording the temperature by shaking.
- * Lubricate the bulb with liquid paraffin or soap and water, when the thermometer is to be used in pup or kitten.
- * Insert the bulb of the thermometer into the rectum and tilt to one side so that the bulb of the thermometer touches the mucous membrane of the rectum.
- * Keep the thermometer in this position for one minute.
- * Take it out, wipe the faeces with cotton and read the temperature directly
- * Roll it until you can see a broad silver band of mercury (Figure 1.9).

Interpretation of thermometer: Thermometer reading will reveal if the temperature of animal being examined is normal (Table 2), above normal (fever) or below normal (subnormal). Based on this finding action taken will vary.

Fever: denotes the elevation of body temperature of animal above normal. It is a general reaction of animal and human

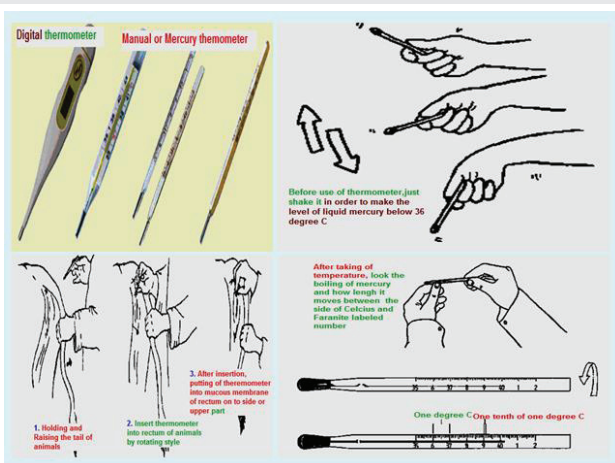


Figure 2: Types of the thermometer and the procedure how to take rectal temperature in an animals. If the reading is not below 36°C, shake the mercury down to the bulb. Use flicking motions, taking care not to hit the thermometer on anything. Take the thermometer out of its case and hold it between the thumb and forefinger [12].

Table 2: Normal range rectal temperature of domestic animals.

Animal species	Temperature °C
Cattle/ Adult	37.8 –39.2
Calve	38.5 –39.8
Horse/Adult	37.2 - 38
Foal	37.5 -38.5
Sheep	38.9 - 40
Goat	38.6 –40.2
Pig/Adult	37.8- 38.9
Piglet	38.9 - 40
Small Dog	38.6 -39.2
Large Dog	37.5 –38.6
Cat	37.8 –39.2
Chicken	41.7

body to the action of infectious agents like bacteria, virus, parasites and exogenous substances like bacterial toxins. Sign of fevers are Animal will refuse to eat either completely or partially (anorexia), hair on the body might be seen standing up, dullness, and dry muzzle. Fever management: There are preparations to reduce temperature. Preparations like paracetamol, phenylbutazone is normally given to control fever (refer drug index for these preparations) in addition keeping animals in cool place [4].

Subnormal temperature / hypothermia: The temperature of animal drops below normal and this occurs when animals get exposed to extreme cold for example when a calf is exposed to heavy rain, when animal is in shock and a clinical condition like milk fever. Here the animal body is unable to regulate body temperature or the heat regulatory mechanism fails to generate heat to compensate the heat loss from the body.

Signs of hypothermia: Shivering, chattering of teeth, cold extremities and skin on touch, and reduced pulse and respiratory rates are observed.

Hypothermia management: Place the affected animal in warm place or provide shelter to protect from rain, rub extremities and apply liniments if available, provide warm porridge if animal has appetite, inject warm DNS / NS, inject calcium preparations in the case of milk fever the temperature will automatically rise.

Pulse taking

Pulse is defined as the regular expansion and contraction of the arterial wall caused by the flow of blood through it at every heartbeat. Pulse gives information with regard to the cardiovascular abnormalities.

It is influenced by exercise, excitement, annoyance, relative humidity, environmental temperature. Pulse can be adapted from the number of heart beats per minute by using stethoscope in less manageable animals. The rhythm of pulse should also be noticed while taking pulse. The pulse rate can rise rapidly in nervous animals or those which have undergone strenuous exercise. In such cases the pulse should be checked again after a period of rest lasting 5 to 10 minutes [4,6].

Procedures how to take pulse rate of domestic animals:

- ▶ Place the digits of fingers on the artery of animals. The anatomical location for arteries of domestic animal is detailed in table 3.
- ▶ Place the tip of the index / middle finger on the artery and applying gentle pressure until the pulse wave can be detected (Figure 3).
- ▶ Count the numbers of beats per minute, which mean count up to 15 minute and multiply by four, notice the quality and rhythm of pulse.
- ▶ The healthy animals may show the result as listed in table 4.

Note the pressure or pulsation of the arteries felt on the finger digits (Figure 3). It is useful to be able to find out how fast the heart is beating. For example, it can help you decide

Table 3: Site of pulse taking in domestic animals.

Animals	Site of pulse taking
Equine	External maxillary artery Transverse facial artery Median artery Great metatarsal artery
Cattle and pig	Middle coccygeal artery Facial artery Median artery
Sheep, Goat, Calf	Femoral artery.
Piglet, Dog and Cat	Femoral artery.

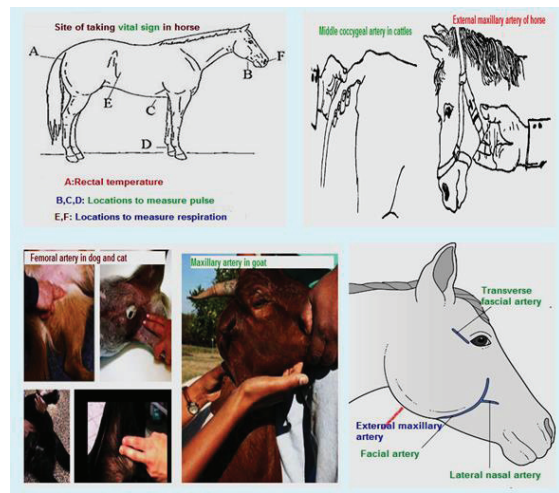


Figure 3: Anatomical location for pulse taking in domestic animals.

Table 4: Normal range of pulse rate in animals.

Animal species	Pulse rate/minute
Cattle	60-90
Young calves	100-120
Horse	28-42
Foal up to 1 year	70-80
Sheep	68 - 90
Goat	68 - 90
Pig	60 - 90
Dog	90 - 130
Cat	110 - 130
Chicken	200 - 400

whether colic is serious. An adult horse's heart beats more slowly than ours, especially when the horse is fit. It takes practice to find the pulse. There are several places where it can be felt. Using a watch with a second hand, count how many beats can be felt in a minute. Feel for it under the bone (mandible) at the side of the face [9]. Or feel for it behind the fetlock joint. Feel for it just above the hoof on the inside of the leg. It is useful to practice finding the pulse here because, if the horse has laminitis, this pulse will feel stronger. If you know what the pulse normally feels like here, it will help you recognize when it is different [10].

Factors influencing pulse

- * Species: Different species of animal have different pulse rate, which is number of rise and fall of arterial wall per minute.
- * Size: Higher in small than in large animals.
- * Age: Higher in young than adult animals.
- * Sex: Male slightly lower than female animal.
- * Parturition & Late stage of pregnancy: Relatively more pulse rate
- * Exercise: Increase pulse rate.
- * Ingestion of food: Cause momentary increase in frequency of pulse.
- * Posture: Pulse rate reduced about 10% when animal is recumbent than when standing [11,12].

Respiration taking

Respiratory movements can be observed at the right flank. Any change in the rate indicates respiratory involvement. Thoracic respiration is seen in animals suffering from acute peritonitis and abdominal respiration in pleurisy. Double expiratory movements are seen in emphysema in horses [3,4].

Types of respiration:

Costal respiration: In this type of respiration thoracic muscles are mainly involved and the movement of the rib cage is more prominent. It is seen in dogs and cats.

Abdominal respiration: This type of respiration is seen in ruminants such as; cattle, goat, sheep and yak. Here the abdominal muscles are involved and movement of the abdominal wall is noticed.

Costo- abdominal respiration: In this type of respiration muscles of both thorax and abdomen are involved so the movement of the ribs and the abdominal wall are noticed. The respiration rate is measured through counting of either contraction or expansion of the thorax and abdomen which can be observed during clinical examination. A method for respiration rate taking includes [6,13].

Inspection: Stand behind and to one side of the animal, and observe the movement of the thoracic and abdominal areas of the body.

Palpation: Put one hand in front of the nostril, feel the exchange of the gas; or put one hand on the lung area or the thorax and feel the respiratory movements.

Auscultation: Use stethoscope, listen to the respiration sound in the trachea or lung area.

Inspiratory or expiratory movements of the chest wall or flank can be counted. In cold weather, exhaled breaths can be counted. If the animal is restless the clinician should count the rate of breathing for a shorter period and use simple multiplication to calculate the respiratory rate in breaths/minute.

The calculation of breathing rate should be conducted by counting inspiration and expiration by looking flank movement or by placing stereoscope for 15 minute and multiply it by 4. After breathing rate taking is finished, the result should be as table 5 for normal animals. However if the abnormality is presented, the result may either greater or lower than normal breathing rate. Mouth breathing is abnormal in cattle and is usually an indication of very poor lung function or a failing circulation.

Visible mucous membrane

The mucous membrane in the eyes, mouth and vagina in the case of females can be examined to determine the health status of an animal. Examination of the mucous membrane should be done in natural light (sunlight) not in the lamplight. The abnormalities of color of mucous membrane are caused by different factors. Some of abnormalities which observed in mucous membranes can be classified to: pallor of the mucous membranes may indicate anaemia caused by direct blood loss or by haemolysis, a blue tinge may indicate cyanosis caused by insufficient oxygen in the blood, a yellow color is a sign of jaundice, the mucosae may be bright red (sometimes described as being 'injected mucous membranes') in febrile animals with septicaemia or viraemia, Bright red coloration of the conjunctiva is often seen, for example, in cases of bovine respiratory syncytial virus infection. A cherry-red coloration may be a feature of carbon monoxide poisoning. A greyish tinge in the mucosae may be seen in some cases of toxemia – such membranes are sometimes said to be 'dirty'. High levels of methaemoglobin, seen in cases of nitrate and/or nitrite poisoning, may cause the mucosae to be brown colored [4,6]. The normal color of different species of animal is listed in table 6.

The color of mucous membrane may change occurs in

Table 5: The respiratory rate of domestic animal per minute.

Species of animals	Respiration rate/minute
Cattle	25 - 30
Horse	8 - 16
Sheep	10 - 20
Goat	10 - 20
Pig	10 - 20
Dog	16 - 30
Cat	20 - 30
Chicken	15 - 30

various diseases as follow by the following [14]:

► **Anaemic mucous membrane.**

- ✓ Blood loss anaemia.
- ✓ Parasitic infestations leading to haemolysis.
- ✓ Tumours or leucosis.
- ✓ Iron deficiency anemia.
- ✓ Long-standing infectious diseases.
- ✓ Exposure to X-rays and some medications.

► **Congested mucous membrane.**

- ✓ High environmental temperatures and exercise.
- ✓ Any disease resulting in fever.
- ✓ Diseases of the heart, brain and its membranes.

✓ Hyperthermia

✓ Conjunctivitis

✓ Trauma

✓ Obstruction of jugular V

► **Yellowish or icteric mucous membrane.**

- ✓ Icterus of jaundice occurs due to increase of blood bilirubin concentration (blood parasites, leptospirosis, hepatitis, cholangitis, cholecystitis and cholangiohepatitis).
- ✓ Infectious anaemia and contagious pleuropneumonia of horses.

► **Chronic gastric dilatation.**

Disease like: Liver diseases, Fascioliasis, Hemolytic anemia, Hypophosphatemia.

- ✓ Cyanosed mucous membrane.
- ✓ Bluish discoloration of visible mucous membranes resulting from presence of reduced haemoglobin in blood capillaries.
- ✓ Carbon monoxide poisoning respiratory diseases
- ✓ Myocarditis, pericarditis.
- ✓ Plant and mineral intoxications.

Swelling of mucous membrane: Inflammation of mucous

membranes results in its swelling; in which case the mucous membranes may also be hot and tender (i.e. showing cardinal signs of inflammation). Marked swelling of conjunctival mucous membranes is characteristic of equine influenza. A slight degree of swelling is noticed in contagious pleuropneumonia of horse and cattle plague, anthrax and fowl diphtheria [14].

Capillary Refill Time (CRT)

Capillary refill time (CRT) is defined as “time required for return of color after application of blanching pressure to a distal capillary bed 15. This is taken by compressing the mucosa of the mouth or vulva to expel capillary blood, leaving a pale area, and recording how long it takes for the normal pink color to return. In healthy animals, the CRT should be less than 2 seconds. CRT of more than 5 seconds is abnormal, and between 2 and 5 seconds it may indicate a developing problem. An increase in CRT may indicate a poor or failing circulation causing reduced peripheral perfusion of the tissues by the blood [6,8].

Methods how to examine mucous membrane by capillary refill time as follow:

- ✓ This is taken by compressing the mucosa of the mouth or vulva to expel capillary blood, leaving a pale area
- ✓ Recording how long it takes for the normal pink color to return.
- ✓ In healthy animals, the CRT should be less than 2 seconds.
- ✓ A CRT of more than 5 seconds is abnormal, and between 2 and 5 seconds may indicate a developing problem.

Physical body condition

Body condition scoring is an important management practice used by producers as a tool to help optimize production, evaluate health, and assess nutritional status. Different scores can be given for individual animal and can further classified as normal, fatty, lean/thin, emaciation 6 (Figure 4).

Condition Score 1: Very thin: This animal's skeletal structure is very prominent. Notice the deep depressions next to the spine, between the pelvis and rib cage, between the hooks and pins, and around the tail head.

Condition Score 2: Thin: The animal's skeleton is still very apparent. The individual spinous processes are clearly visible, but there is a small amount of fat tissue over the spine, hooks, and pins.

Condition Score 3: Medium (Normal body condition): The animal appears smooth over the spine, ribs, and pelvis and the skeletal structure can be easily palpated. The hooks and pins are still discernible, with a moderate, rather deep depression between the pelvis and rib cage, hooks and pins, and around the tail-head.

Condition Score 4: Fat: There are no spinous processes detectable, and no depression in the loin area, which gives the top-line of the animal a flat, tabletop appearance. The ribs can no longer be felt, and the pelvis can only be felt with firm

Table 6: Normal color of mucous membrane of different animals.

Animal	Color of mucous membrane
Cattle, sheet and goat	Pale pink
Horse	Pale roseate
Pig	Reddish
Dog	Pale roseate
Cat	Pale pink

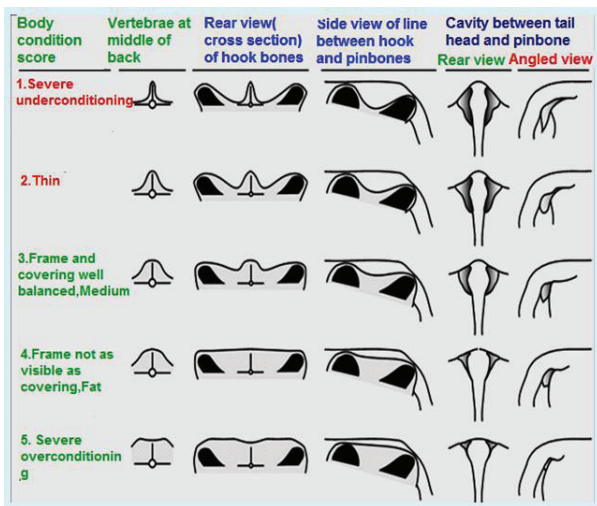


Figure 4: Body condition score of animals.

pressure. The hooks and pins have a rounded appearance due to areas of fat covering.

Condition Score 5: Very Fat: The animal appears rounded and smooth with a square-shaped appearance, because of the amount of fat filling in the loin. The skeletal structure is no longer visible, and can only be palpated with excessive pressure.

Normal demeanor: When, on being approached, an animal makes a normal response to external stimuli, such as movement and sound, the demeanor is said normal (bright). Normal reaction under these circumstances may consist of elevating the head and ears, turning towards and directing the attention at the source of stimuli, walking away and evincing signs of attack or flight [8].

Abnormal demeanor: Behavioral change/ response to external stimuli. The Abnormal demeanors in domestic animals are as follow list [6,8].

- ✓ Decreased response (depression): dull (apathetic); dummy state; comma.
- ✓ Excitation or increased response: apprehension (mildly anxious); restlessness; mania; frenzy.
- ✓ Posture: It denotes the anatomical configuration when they remain in stationary situation. How does it stand? How does it sit? How does it lie?

- ✓ Gait: It indicates about the locomotory process of an animal.
- ✓ Body conformation: shape and size of the different body regions relative to other regions.

References

1. Kahn CM (2010):Merck Veterinary Manual. 10th edn. Whitehouse Station,Merck, NJ, USA.
2. Fundamentals of Veterinary Medicine, Clinical Examination UNIT2 (2006): website available at; http://cms.cnr.edu.bt/cms/files/docs/File/VM%2011/UNIT%202_%20Clinical%20Examination.doc
3. Kelly WR (1974) Veterinary Clinical Diagnosis. 2nd edn. Bailliere Tindal &Casell, London, UK.
4. Radostits OM, Gay CC, Hinchcliff KW, Constable PD (2007).Veterinary Medicine: A textbook of the diseases of cattle, sheep, pigs and goats, horses.10th edn. St. Louis: Saunders (Elsevier).
5. Ajello, S.E. (1998).The Merck Veterinary Manual, 8th edition, Published by Merck and Company, INC, USA
6. Jackson P, Cockcroft P (2002) Clinical Examination of Farm Animals. Blackwell Science, UK.
7. Riviere JE, Papich MG (2001) Veterinary Pharmacology & Therapeutics. 9th edn. Wiley-Blackwell, USA.
8. Duguma A (2016). Practical Manual on Veterinary Clinical Diagnostic Approach. J Vet Sci Technol 7: 337. doi:14.4172/2157-7579.1000337
9. Chauhan RS, Agarwal DK (2008) Textbook of Veterinary, Clinical and Laboratory Diagnosis. 2nd edn. Jaypee Publishers, New Delhi, India.
10. Hadrill, D. (2002). Horse healthcare. A manual for animal health workers and owners.
11. Factor affecting pulse rate. Website available at: <http://www.aun.edu.eg/developmentvet/Temp%20Pulse%20Resp%20.pdf>.
12. Fulwider, W. K. (2014). 8 Dairy Cattle Behaviour, Facilities, Handling, Transport, Automation and Well-being. Livestock Handling and Transport: Theories and Applications, 116
13. Radostits OM, Mayhew IG, Houston DM (2000). Veterinary clinical examination and diagnosis. London: WE Saunders.
14. Internal medicine. Website available at:<http://www.aun.edu.eg/developmentvet/Internal%20medicine/amly3.htm>
15. Gorelick, M. H., Shaw, K. N., and Baker, M. D. (1993). Effect of ambient temperature on capillary refill in healthy children. Pediatrics, 92(5), 699-702.